

Effect of Autonomization Surgical Techniques on Transverse Rectus Abdominis Myocutaneous Flaps – Experimental Study in Female Rats

Rui Lopes Filho, MD¹
Alcino Lázaro da Silva, MD²

- 1] Senior Member of SBCP. Master's Degree in Medicine from the Universidade Federal de Minas Gerais.
- 2] Head Professor of Digestive System Surgery in the Department of Medicine of Universidade Federal de Minas Gerais.

Address for correspondence:

Rui Lopes Filho, MD

R. Cônego Rocha Franco, 133 – ap. 302
30430-000 – Belo Horizonte – MG
Brazil

Phone: (55 31) 3337-8597

Keywords: Autonomization; flap; skin necrosis; histology.

ABSTRACT

A study was conducted on the effect of autonomization surgical techniques on monopediculated transverse rectus abdominis mycutaneous flaps in female rats. Animals in Group A (control) were submitted to the flap procedure proposed for the study, consisting of an incision, removal of the fragment in area 3 and detachment of the flap up to the lower abdomen, followed by on site suture. Animals in groups B, C, D, E, F, G, and H were submitted to different autonomization surgical techniques, seven days before the flap procedure proposed for the study. The area of necrosis in relation to the total flap healing area was assessed by using a sheet of standard graph paper, a fine point Pilot® pen and a transparent cast. A light microscopy histological study was performed on the fragments removed from the contra lateral end of the vascular pedicle of the flap. The autonomization surgical technique that divided the cranial portion of rectus abdominis muscles bilaterally and cauterized both upper deep epigastric vessels used on group C animals was more effective in reducing the area of necrosis of the flap studied, and did not result in histological changes in the fragments examined.

INTRODUCTION

The transverse rectus abdominis mycutaneous flap was described by Hartrampf *et al.* (1982)⁽¹⁾ and Gandolfo (1982)⁽²⁾, and is considered an excellent flap for breast reconstruction after mastectomy.

Risk factors⁽³⁾ included vascular involvement and necrosis of the transverse rectus abdominis mycutaneous flap with a non-dominating vascular pedicle, which were more frequent in obese patients or those who smoked

or had abdominal scars, chronic lung conditions, severe cardiovascular conditions, psychological problems or an inexperienced surgeon.

Surgical autonomization led to an intentional and scheduled ischemia, resulting in an increase in internal vascularization and a reduction in the area of necrosis of cutaneous⁽⁴⁾ and myocutaneous flaps with a deficient blood flow, according to previous studies performed in animals^(5, 6, 7, 8, 9).

The transverse rectus abdominis mycutaneous flap model in rats was chosen for the study. This experimental flap model proposed by Ögzentas *et al.* (1994)⁽⁶⁾ greatly resembles the transverse rectus abdominis mycutaneous flap in humans, in regard to myocutaneous perforans and nutrition from the non-dominating vascular pedicle.

MATERIAL AND METHOD

We used eighty Wistar female rats, weighing between 250 g and 300 g, kept under the same conditions at the experimental laboratory of the graduate course on surgery at the Minas Gerais Federal University Medical School.

Anesthesia was given by the intramuscular route, associating 10 mg/kg of Ketamine Hydrochloride (*Ketalar*[®]) and 0.1 mg/kg of 2-(2,6-xilidine)-5,6-dihydro-4H-1,3-Tiazine Hydrochloride (*Rompun*[®]).

The 4.2 cm x 2.1cm rectangular transverse rectus abdominis mycutaneous flap model used was divided into areas 1, 2, and 3 (Fig. 1).

The flap procedure consisted of incision, fragment removal in area 3 and detachment of the flap up to the lower abdomen (Figs. 2 and 3). After complete detachment of the flap, nourished by deep lower epigastric vessels and of the rectus abdominis, the flap was sutured with monofilament 4-0 nylon on site.

The animals in group A (control) were submitted only to the flap procedure proposed for the study. The animals in groups B, C, D, E, F, G and H were submitted to different autonomization surgical techniques (Table I) (Figs. 4 and 5). After the seven-day autonomization period, animals were submitted to a flap procedure, similar to the one performed on the animals in group A (control).

The area of necrosis of flaps was measured on the fifth post-surgical day, using a transparent cast, a fine point



Fig. 1 – Drawing of the transverse rectus abdominis mycutaneous flap with areas 1, 2, and 3. Projection of the rectus abdominis muscle in red. The arrow shows the segment to be sent for histological exam.

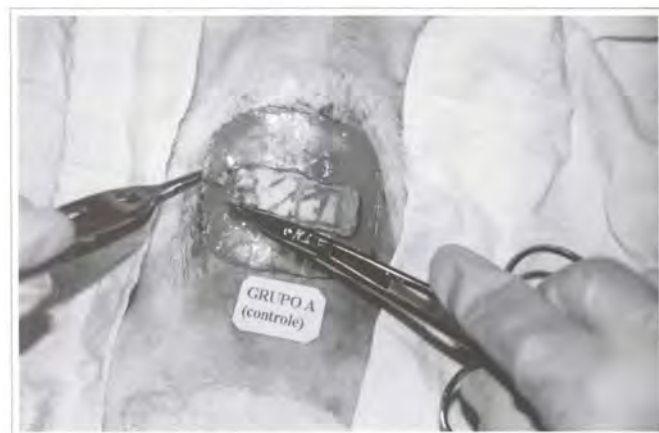

Fig. 2 – Fragment of area 3 being removed during the surgical procedure.

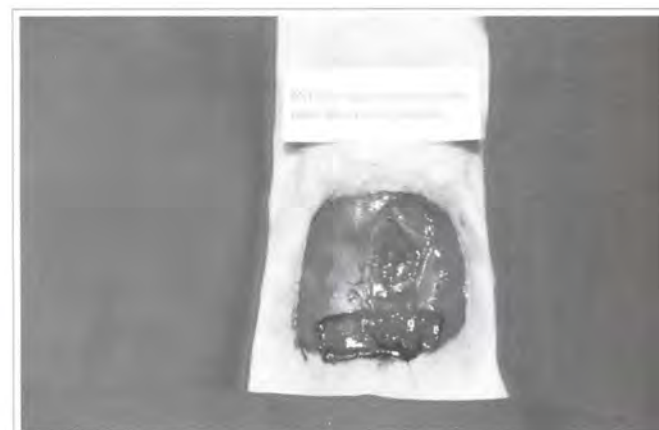

Fig. 3 – Transverse rectus abdominis mycutaneous flap detached and flipped up to the lower abdomen.

Pilot® pen and a sheet of standardized graph paper. Then, the percentage of the area of necrosis in relation to the total flap healing area was calculated.

Fragments removed from flap area 3 were embedded in paraffin blocks, and cut into five micra thick histological slices on a manual microtome, then stained with hematoxylin and eosin (H.E.) for light microscopy studies.

RESULTS

MACROSCOPIC CHANGES

The areas of necrosis began after approximately 48 hours and were defined on the fourth post-surgical day (Fig. 6).

The animals in group A (control) had necrosis in areas 2, 3 and the lateral part of area 1.

The animals in group B had necrosis in area 3 and part of area 2.

The animals in group C had necrosis only on the lateral part of area 3. There was total flap survival in six female rats.

The animals in group D had necrosis in area 3 and on the lateral part of area 2. There was total flap survival in three female rats.

The animals in group E had necrosis in area 3 and part of area 2. There was total flap survival in six female rats.

The animals in group F had necrosis in area 3 and part of area 2. There was total flap survival in three female rats.

The animals in group G had necrosis in area 3 and part of area 2. There was total flap survival in one female rat.

The animals in group H had necrosis in area 3 and part of area 2. There was total flap survival in one female rat.

STATISTICAL ANALYSIS

The F test indicated a significant difference among groups and the test for minimum significant differences (MSD) allowed for multiple comparisons between each group (Table II). The graph of percent-

age of necrosis area in each group was plotted as a histogram (Fig. 7).

MICROSCOPIC CHANGES

The fragments removed from the animals in groups A, B, C and G showed no histological changes (Fig. 8).

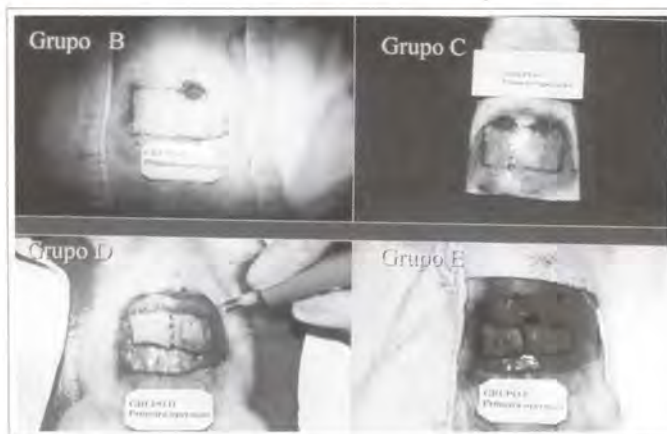


Fig. 4 – Autonomization surgical techniques used on the animals in groups B, C, D, and E.

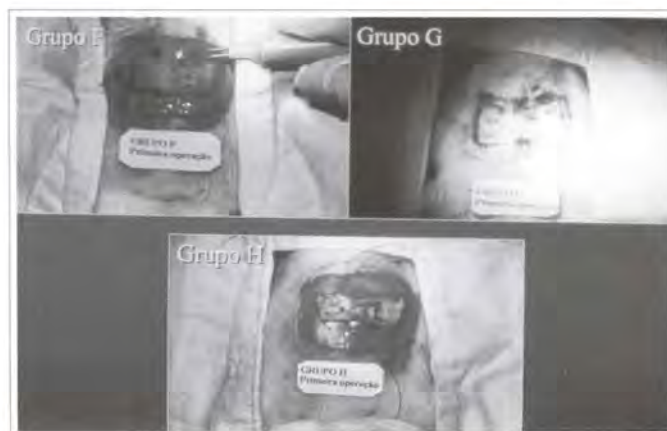

Fig. 5 – Autonomization surgical techniques used on the animals in groups E, G, and H.

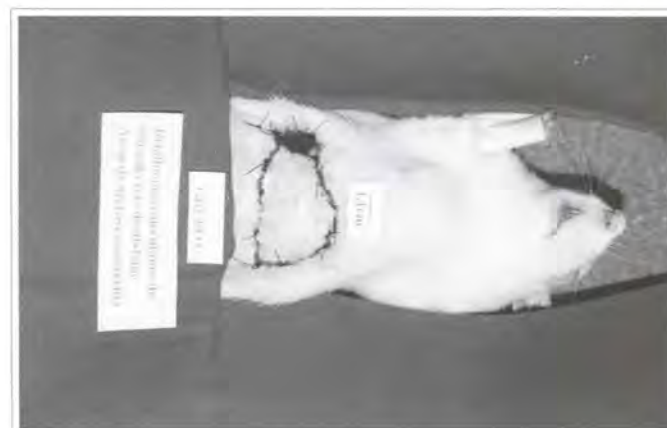

Fig. 6 – Area of necrosis in the transverse rectus abdominis myocutaneous flap.

The tissues in the fragments removed from the animals in groups D, E, F, and H presented steatonecrosis, granulation tissue, abundant inflammatory infiltrate, fascia neovascularization and abscesses (Fig. 9).

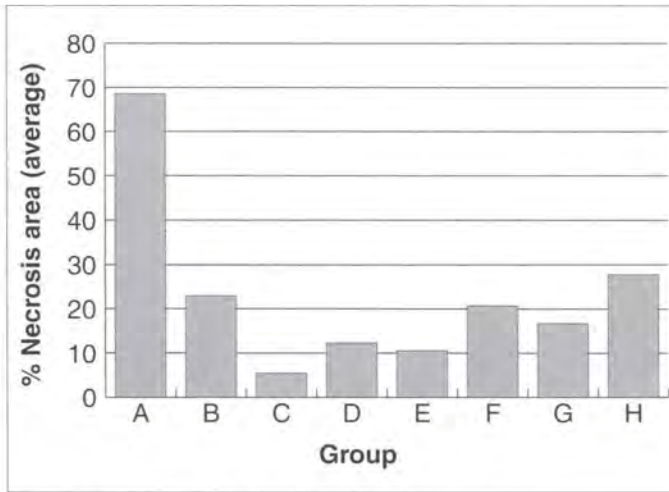


Fig. 7 – Percentage of area of necrosis in each group.

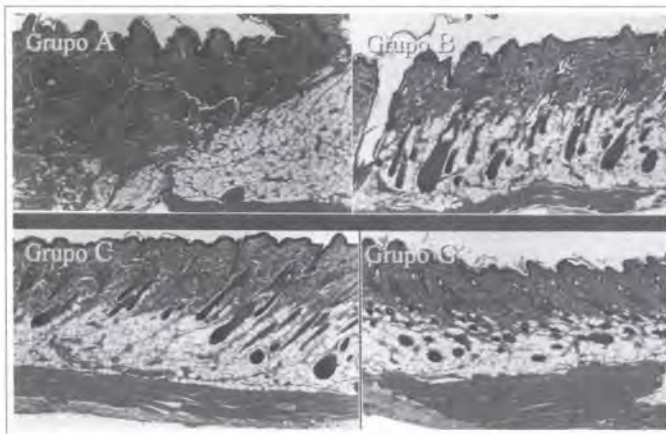


Fig. 8 – Histological slices of groups A, B, C, and G, stained by H. E. (40x).

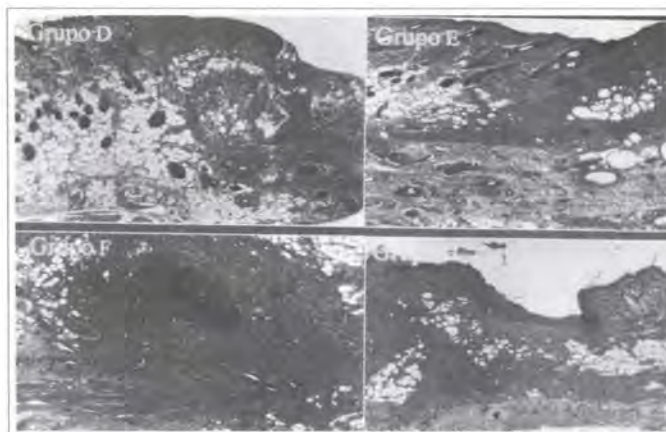


Fig. 9 – Histological slices of groups D, E, F, and H, stained by H. E. (40x).

DISCUSSION

The transverse rectus abdominis mycutaneous flap with a non-dominating vascular pedicle, usually used for breast reconstruction, led to a higher incidence of complications, such as skin necrosis. Autonomization reduces flap skin necrosis according to previous studies (4, 5, 6, 7, 8, 9).

One disadvantage in the present study in regard to working with female rats was tissue laxity and the small size of the abdominal wall structures in these animals, which demanded greater technical care and the use of a 2.5x magnifying glass.

The anesthetic technique used proved satisfactory, by associating the analgesic effect of ketamine hydrochloride (*Ketalar*[®]) and the analgesic muscle relaxant action of 2-(2,6-xilidine)-5,6-dihydro-4H-1,3-tiazine hydrochloride (*Rompun*[®])⁽¹⁰⁾.

The autonomization period chosen for observing the animals was seven days, which was the period responsible for significant changes leading to the reduction of the area of necrosis of the transverse rectus abdominis mycutaneous flap in the rats⁽⁸⁾.

Table I

Groups	Autonomization Surgical Techniques
B	Cranial division of the left rectus abdominis muscle. Cauterization of left deep upper epigastric vessels.
C	Cranial division of both rectus abdominis muscles. Cauterization of both deep upper epigastric vessels.
D	Skin incision without detachment.
E	Skin incision without detachment. Cranial division of the left rectus abdominis muscle. Cauterization of left deep upper epigastric vessels.
F	Skin incision without detachment. Cranial division of both rectus abdominis muscles. Cauterization of both deep upper epigastric vessels.
G	Cranial division of the left rectus abdominis muscle. Cauterization of left deep upper epigastric vessels. Detachment of area 2. cauterization of myocutaneous perforans and introduction of a fine silicone blade in the area.
H	Skin incision. Detachment of area 2, cauterization of myocutaneous perforans and introduction of a fine silicone blade in the area.

Autonomization surgical technique used in groups B to H.

Table II

Group	Measurements					f / conclusion
	Min	Max	Average	SD	VC	
A	62.50	75.00	68.61	4.80	7.00	
B	5.66	40.62	22.91	11.91	51.98	<0,001
C	0,00	14.55	5.46	7.07	129.50	
D	0,00	31.25	12.34	13.36	108.32	A > all
E	0,00	44.26	10.57	165.17	152.67	H > (D, E and C)
F	0,00	42.49	20.69	16.90	81.69	B > (E and C)
G	0,00	34.72	16.71	9.24	55.25	(F and G) > C
H	0,00	41.86	27.77	14.60	52.59	

Characteristics of flaps assessed in relation to the percentage of area of necrosis.

Note: Group A = Control / Groups B to H = autonomization surgical techniques. Significance probability refers to the F-test of analysis of variance.

The F test of analysis of variance (ANOVA) showed a significant difference between groups and the test for minimum significant differences allowed for multiple comparisons between groups^(11, 12).

The autonomization procedure used in the animals in group H, the segment in which area 2 was detached and myocutaneous perforans cauterized, associated with the incision in the borders of the flap, was less effective in reducing the area of necrosis of the flap, contrary to what has been found in the literature⁽⁹⁾.

The fragments examined from the animals in groups D, E, F, and H presented histological changes that were compatible with inflammatory process and tissue healing, according to the histological studies in rat tissue described in the literature^(13, 14).

The experimental study allowed us to conclude that the autonomization procedure performed on the animals in group C was more effective in reducing the area of necrosis of the transverse rectus abdominis myocutaneous flap with a non-dominating vascular pedicle and did not lead to histological changes in the tissues of the fragments examined.

REFERENCES

1. Hartrampf CR, Sheflan M, Black PW. Breast reconstruction with a transverse abdominal island flap. *Plast Reconstr Surg.* 1982; 69(2):216-25.
2. Gandolfo EA. Breast reconstruction with a lower abdominal myocutaneous flap. *Br J Plast Surg.* 1982; 25:452-7.
3. Hartrampf CR Jr. The transverse abdominal island flap for breast reconstruction: A 7- year experience. *Clin Plast Surg.* 1988; 15(4):703-16.
4. Milton SH. Experimental studies on island flaps II. Ischemia and Delay. *Plast Reconstr Surg.* 1972; 49(4):444-7.
5. Dorion D, Boyd JB, Pang CY. Augmentation of transmidline skin perfusion and viability in transverse rectus abdominis myocutaneous (TRAM) flaps in the pig. *Plast Reconstr Surg.* 1991; 88(4):642-9.
6. Özgzentas HE, Shenaq S, Spira M. Study of the delay phenomenon in the rat tram flap model. *Plast Reconstr Surg.* 1994; 94(7):1018-24.
7. Hallock GG, Rice DC. Evidence for the efficacy of TRAM flap delay in rat model. *Plast Reconstr Surg.* 1995; 96(6):1351-7.
8. Restifo RJ, Ahmed SS, Isemberg SJ, Thomson JG. Timing, magnitude, and utility of surgical delay in the TRAM flap. I: Animal studies. *Plast Reconstr Surg.* 1997; 99(5):1211-6.
9. Restifo RJ, Ahmed SS, Rosser J, Zahir K, Zink J, Lalikos JA, Thomson JG. TRAM flap perforator ligation and delay phenomenon: development of an endoscopic / laparoscopic delay procedure. *Plast Reconstr Surg.* 1998; 101(6):1503-11.
10. Massone E. Anestesiologia veterinária – farmacologia e técnicas. In: Técnicas anestésicas em animais de laboratório. 3. ed. Rio de Janeiro: Guanabara Koogan; 1999. Cap. 10; p. 97-102.
11. Johnson R, Bhathacharyya G. Statistics principles and methods. New York:Wiley; 1986. p. 578.
12. Montgomery DC. Design and analysis of experiments. New York:Wiley; 1991. p. 649.
13. Alfonso CG, Perez FP. Patología quirúrgica de los animales domésticos. Barcelona:Científico-médica; 1982. Cap. 3; p. 119-74.
14. Cheville NF. Introdução a Patologia Veterinária. Manole:São Paulo; 1994. Cap. 19; p. 321-42.