

# Use of microsurgical flaps for the treatment of burn patients: a literature review

## *Uso de retalhos microcirúrgicos em pacientes queimados: revisão da literatura*

BRUNO BARROS DE AZEVEDO  
COUTINHO<sup>1</sup>  
MARINA BUAINAIN BALBUENA<sup>1</sup>  
TATYANNE FERREIRA DA  
SILVA<sup>1</sup>  
FÁBIO TACLA SAAD<sup>1</sup>  
KLEDER GOMES DE ALMEIDA<sup>2</sup>  
PAULETE YURI NUKARIYA  
GOMES DE ALMEIDA<sup>3</sup>

Study conducted at the  
Associação Beneficente  
Santa Casa de Campo Grande  
(Beneficent Association of  
Campo Grande Santa Casa),  
Campo Grande, MS, Brazil.

Submitted to SGP (Sistema de  
Gestão de Publicações/Manager  
Publications System) of RBCP  
(Revista Brasileira de Cirurgia  
Plástica/Brazilian Journal of  
Plastic Surgery).

Article received: October 2, 2011  
Article accepted: December 1<sup>st</sup>, 2011

### ABSTRACT

Patients with severe burns complicated by joint involvement and exposure of noble structures require immediate local cover, which can be achieved using a variety of surgical procedures. Local flaps are the first choice due to the simplicity of their preparation and the resulting acceptable cover. However, the tissue adjacent to the burned area is often of low quality as a consequence of local changes that mainly affect blood circulation. When local flaps cannot be used, distant and/or microsurgical flaps can be applied. However, distant flaps generally require reconstructions performed in separate surgical procedures, which can prolong bed rest and immobilization of the patient. For more than 3 decades, microsurgery has been used to repair significant tissue losses in a single surgical procedure. This technique enabled the use of tissue transplantation for the repair of burn sequelae. Often in association with other established surgeries, such as skin graft or tissue expansion, these procedures provide better functional and aesthetic results. In the present study, aspects of this therapeutic strategy, as well as the indications, contraindications, and technical details of tissue transplantation are discussed.

**Keywords:** Burns. Microsurgery. Tissue transplantation.

### RESUMO

Pacientes com queimaduras graves, em casos de acometimento articular e de exposição de estruturas nobres, necessitam de cobertura local o mais breve possível. Em ambas as situações referidas, faz-se necessária a realização de procedimentos que proporcionem cobertura adequada de tais tecidos e estruturas. Retalhos locais são a primeira escolha, em decorrência da simplicidade de sua confecção e da boa cobertura propiciada por eles. Entretanto, no universo dos pacientes queimados, as áreas contíguas à área lesionada geralmente apresentam-se queimadas ou com tecidos de baixa qualidade, em decorrência de alterações locais, principalmente na circulação. Quando não é possível o emprego de retalhos locais, utilizam-se retalhos à distância e/ou microcirúrgicos. Entretanto, retalhos à distância geralmente necessitam de reconstruções em tempos diversos e, em alguns casos, imobilização prolongada no leito. Com a introdução da técnica microcirúrgica para reparo de grandes perdas de substância em tempo único, há mais de três décadas, em nosso meio, o transplante de tecido passou a ser uma realidade no arsenal técnico do cirurgião para reparo dessas graves sequelas, proporcionando resultados funcionais e estéticos mais aceitáveis, associado ou não a outros métodos consagrados, como expansão tecidual ou enxertia cutânea. Neste trabalho, são discutidos os aspectos relativos a esse arsenal terapêutico, suas indicações e contraindicações, e os aspectos técnicos relativos a cada região.

**Descritores:** Queimaduras. Microcirurgia. Transplante de tecidos.

1. Aspirant member of the Sociedade Brasileira de Cirurgia Plástica (Brazilian Society for Plastic Surgery) – SBCP, plastic surgery resident at the Associação Beneficente Santa Casa de Campo Grande (Beneficent Association of Campo Grande Santa Casa), Campo Grande, MS, Brazil.
2. Full member of SBCP, member of the Sociedade Brasileira de Microcirurgia (Brazilian Society of Microsurgery), assistant professor of Disciplina de Morfofisiologia da Universidade Federal de Mato Grosso do Sul (Morphophysiology at the Federal University of Mato Grosso do Sul), Preceptor of the Residency Program of Plastic Surgery at the Associação Beneficente Santa Casa de Campo Grande (Beneficent Association of Campo Grande Santa Casa), Campo Grande, MS, Brazil.
3. Specialist member of SBCP, plastic surgeon at the Hospital Regional de Mato Grosso do Sul (Regional Hospital of Mato Grosso do Sul), Campo Grande, MS, Brazil.

## INTRODUCTION

Patients with severe burns, in particular those presenting with joint involvement with major integumentary losses, consistently evolve with significant cicatricial retractions that lead to aesthetic and functional disorders. Moreover, potentially exposed noble structures such as bones, tendons, blood vessels, and central and peripheral nervous system components require immediate local cover. To provide adequate cover, these defects can be repaired using local, distant, or microsurgical flaps, discarding the possibility of using a graft because noble structures require additional protection and prevention from scarring sequelae.

Based on the assumption that the best reconstruction is the simplest procedure that can restore form and function without resulting in sequelae in the donor area, Mathes and Nahai proposed the principle of the reconstructive ladder. This allows selection of the indicated surgical technique based on its simplicity and on the specific features of each lesion. Taking this into account and considering the cases mentioned above, it is necessary to exclude *a priori* primary synthesis and grafts due to the specificity of the lesion in question<sup>1</sup>.

Local flaps are the first choice because they are simple to prepare and provide adequate cover. However, in burn patients, the tissues adjacent to the injured area are often damaged because of the burn or are of low quality as a consequence of local changes that mainly affect blood circulation. The production of a local flap is therefore often difficult and its viability may be compromised.

When local flaps are not a viable option, distant and/or microsurgical flaps are used. However, reconstructions with distant flaps generally involve different surgical procedures, which often prolongs the period of bed rest and immobilization. This is undesirable in burn patients because of the possibility of thromboembolisms due to extensive trauma and the inconvenience of multiple surgical procedures.

Microsurgery has been in use for more than 3 decades for the repair of significant tissue losses in a single surgical procedure. This technique enables the surgeon to repair serious burn sequelae with improved functional and aesthetic results. Microsurgical procedures can be associated with other established methods, such as skin graft or tissue expansion<sup>2</sup>.

Initially, microsurgical transplants were performed in patients with burn sequelae. The procedure was later modified, and the indications for microsurgery increased as surgeons acquired more experience with the procedure, resulting in the application of vascular microsurgery for the repair of more complex cases and acute burns. Currently, the tendency is to perform microsurgical reconstruction in the acute phase in an attempt to prevent sequelae<sup>3</sup>.

Microsurgical flaps are beneficial because they enable the surgeon to close deep lesions in a single procedure,

resulting in lower infection rates, and decreased morbidity and hospitalization time. This leads to earlier rehabilitation of the patient and preservation of the function of the affected region. In tissue retractions, which are common in burn sequelae, free flaps provide sufficient vascularized tissue with features similar to those of the receiving area, resulting in reconstitution of the local anatomy and improved aesthetic and functional results<sup>3</sup>.

## INDICATIONS AND CONTRAINDICATIONS OF MICROSURGERY

The indications for microsurgical flaps include limb injury sequelae caused by extensive electrical and deep thermal burns, for which local flaps cannot be employed.

Further, microsurgical flaps are generally used in cases of exposure of noble structures requiring immediate cover. In keeping with this notion, early sequential debridements are performed in all the devitalized tissues, and microsurgical transplantations are carried out within a maximum of 3 weeks. Although adopted by many surgical services, this procedure is not recommended as a standard treatment.

The criteria for the exclusion of patients (contraindications) are systemic or localized vascular disease, diabetes, arterial hypertension, previous radiotherapy, severe heart disease with or without arrhythmia, comorbidities that might lead to significant clinical-surgical alterations, sepsis, and/or local infection.

Microsurgical transplants, in particular those applied to the treatment of electrical burns or ionizing radiation<sup>4,5</sup>, should be carefully planned in advance, as the vascularization (receiving vessels and/or donors) in the area in which the microanastomosis is performed might be compromised, increasing the risk of vessel thrombosis.

The presence of pulses, routinely assessed by *Doppler* ultrasonography or angiotomography of the receiving vessels, should be verified to establish an appropriate preoperative plan<sup>3</sup>.

Free flaps used in burn reconstructions can be divided into myocutaneous, muscular, cutaneous, and fasciocutaneous. Myocutaneous and muscular flaps, which are mainly used to fill cavities, provide better control of the infection rate and are preferred for the repair of areas undergoing radical debridements, as in the case of electric trauma. Cutaneous and fasciocutaneous flaps show efficient local adaptation and provide a thin and efficient cover, which is often required, when applied to the limbs<sup>3</sup>.

Taking into consideration the extension, location, and the structures or tissues requiring repair, the specific indications for microsurgical transplants are as follows:

- skull: musculocutaneous and muscular flaps;
- face: cutaneous, fasciocutaneous, and osteofasciocutaneous flaps;

- neck: cutaneous, fasciocutaneous, and muscular flaps;
- hand and foot: fasciocutaneous, cutaneous, and muscular flaps;
- exposure of osteotendinous structures (long bones): muscular flaps.

### ANATOMICAL AREA INVOLVED

Areas in which the skin is thinner, such as the upper limbs (dorsal hand and fingers), lower limbs (anterior portion of the leg and dorsum of the foot), face, and the cervical region, require a matching skin cover, and in these cases the use of fasciocutaneous flaps is indicated. Burns caused by electricity, combustion, or contact may be the cause of damage in these regions<sup>3</sup>.

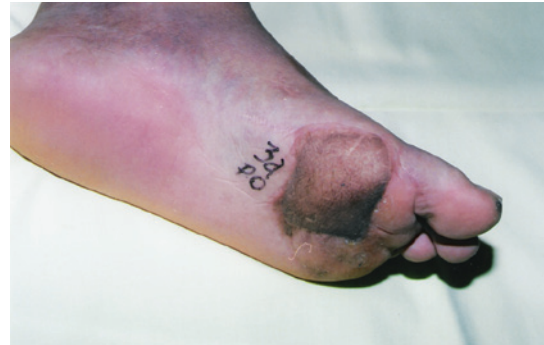Areas showing more extensive tissue damage, such as those undergoing radical debridement with possible bone exposure, require large amounts of donor tissue. In these situations, muscular or myocutaneous flaps are often suggested<sup>3</sup>.

For the repair of hands and feet, the quality of the cover should meet the functional requirements. In the repair of hand defects, the aim is to create a pincer that, when the patient attempts to grip an object, provides a good opening of the interdigital space and preserves the length and sensitivity of the digital pulp. This enables the patient to regain thumb opposition and grasp objects. Regarding the foot, especially the sole, the preservation of stability and sensitivity are the main goals when the repair involves areas of plantar support. Lateral arm and forearm fasciocutaneous flaps are preferred for the repair of palms and soles because they are thin, and when transferred to support areas, they increase stability and provide satisfactory aesthetic results without causing ulcers or persistent edema. Figure 1 shows the appearance of the plantar cover of an electrical burn area 3 years after surgery. In this case, 2 surgical procedures were performed to decrease the subcutaneous cellular tissue.

### Head and Neck Covers

The major challenges in the repair of head and neck burns are to obtain sufficient cover of scalp and skull tissue losses and to repair severe cervicothoracic adhesions while preserving the aesthetic and functional properties of the face<sup>6</sup>. Microsurgical flaps have been used to replace areas showing retractions, which may present with adhesions to deep planes (late), or those that require cover of noble structures (early).

In the surgical treatment of cervicothoracic adhesions, which lead to significant limitations related to neck extension at varying degrees, the use of skin grafts or local flaps to replace the scar tissue has been questioned after consideration of the short- and long-term aesthetic and functional results. This procedure thus requires improvements, and new strategies aimed at increasing cervical extension in the presence



**Figure 1** – An electric current burn in the plantar region covered with a lateral arm flap after a post-operative period of 3 years.

of late scar retraction are essential. The ideal flap should be thin and long enough to cover a large region and prevent the development of late retractions.

To repair these large areas, the use of thin and/or previously expanded skin flaps, which can be associated with bone tissue in jaw reconstructions, is necessary. The most frequently used flaps are the scapular, rectus abdominis, and osteomyocutaneous flaps with inclusion of the fibula.

The so-called “pre-molded” flaps, which are expanded in the donor area<sup>7</sup>, might undergo secondary retractions when transferred to the receiving region, requiring additional surgeries. However, in cases involving the cervical contour, for which a more elastic tissue is needed, the microsurgical flap has provided excellent functional results, reducing the time requirement for the use of orthoses and compressive meshes, and allowing earlier physical therapy intervention.

### Upper Limb and Hand Covers

The repair of upper limb injuries, mainly those involving the middle and distal thirds of the posterior or anterior forearm; those showing exposure of vessels, nerves, or tendons; and defects involving the palm and dorsum of the hand, require immediate cover. In keeping with this notion and considering the preservation of the flexo-extension function of the forearm, a muscular flap of the latissimus dorsi or gracilis muscles should be used. For the repair of the dorsum and palm of the hand, a lateral arm flap is preferred. Figure 2 shows a hot oil burn in the palmar region that was covered with a lateral arm flap anastomosed to the radial artery and vein.

Although electrical burns constitute only a small proportion of thermal-related injuries, most electric burns affect the flexo-extensor apparatus as well as the median and ulnar nerves. Whenever possible, in late reconstructions, deep structures should be repaired in a single surgical procedure. In primary repairs, priority should be given to the skin to enable the subsequent reconstruction of deep structures such as muscles and tendons. Following the complication period



after the transplant, the functional reconstruction of the gracilis muscle (muscle-tendon) should be planned, followed by the reconstruction of the flexor or extensor apparatus of the forearm.

The use of several proximal flaps in different surgical procedures can result in a delay of the functional rehabilitation of the affected area. Extensive areas could be covered in a single surgical procedure using microsurgical flaps, which allows an early functional rehabilitation of the limb.

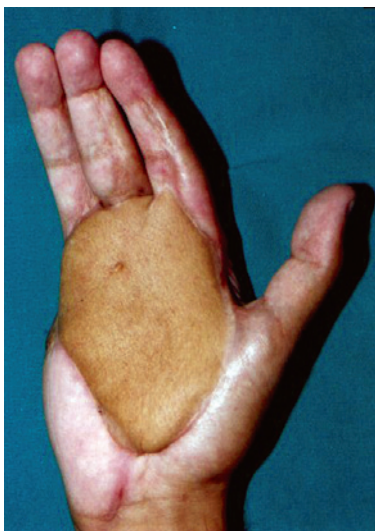
The choice of microsurgical flap depends on the experience of the specific surgical service and on the complexity of each case.

The requirement of bridge grafts for arterial or venous anastomoses is due to the presence of vessels near the injury site that are not patent or reliable for anastomosis. Importantly, the preservation of the function of the hand or upper limb is the first priority in the repair of injuries involving these regions, and this consideration should determine the choice of treatment.

Figure 3 shows a patient with an electric burn that evolved to transmetacarpal amputation that was covered with lateral arm flap.

### Lower Limb Covers

Functional sequelae resulting from burns in the lower limb are less common. However, retractions in the popliteal fossa, dorsal region of the foot, toes, and ankle cause severe functional deficiencies in the lower limb, which limit ambulation and musculoskeletal development. In these regions, conventional procedures such as zeta-plasty, grafts, and local flaps are effective for the repair of most retractions.



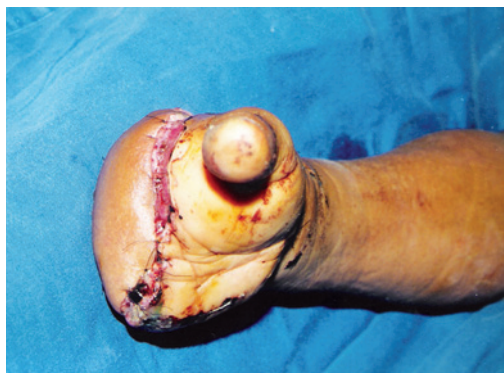**Figure 2** – Palmar region covered with a lateral arm flap presenting sufficient digital extension.

The challenges in the lower limb are associated with plantar defects and injuries causing joint movement limitations, which may or may not be repaired using conventional methods. For the repair of ankle burns, the use of the muscular flap of the gracilis is preferred, whereas in cases of major losses of the dorsum of the foot and lower-middle third of the leg, the latissimus dorsi flap is the first choice, especially in the presence of bone exposure or losses. Figure 4 shows the covering of an area with extensive tissue loss in the dorsum of the foot and ankle and bone exposure.

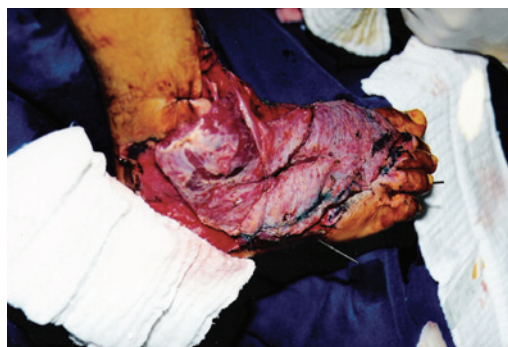The use of a lateral arm flap to cover the plantar region provided stability and satisfactory aesthetic and functional results, without the appearance of a plantar ulcer. However, the presence of a significant scar in the donor area was observed.

### CONCLUSIONS

Microsurgical flaps are indicated for complex reconstructions in burn patients, especially when the lesions involve noble structures and joints. Clearly, this is an exceptional procedure adopted only when simpler techniques,



**Figure 3** – Transmetacarpal amputation covered with a lateral arm flap in a victim of an electric burn.



**Figure 4** – Dorsum of the foot and ankle covered with a latissimus dorsi flap.

such as local flaps, cannot be employed due to the morbidity associated with surgery. However, if indicated properly, microsurgical flaps provide excellent results when used for the reconstruction of noble structures, with preservation of functional and aesthetic properties.

### REFERENCES

1. Mathes SJ, Nahai F. Reconstructive surgery: principles, anatomy, and technique. London: Churchill Livingstone; 1997. p. 617-42.
2. Horibe EK, Pinto WS, Yamaguchi CT. Uso de expansores de tecidos no tratamento de sequelas de queimaduras. Rev Bras Cir. 1988;78(2): 117-24.
3. Milcheski DA, Busnardo F, Ferreira MC. Reconstrução microcirúrgica em queimaduras. Rev Bras Queimaduras. 2010;9(3):100-4.
4. Hunt JL, McManus WF, Haney WP, Pruitt BA Jr. Vascular lesions in acute electric injuries. J Trauma. 1974;14(6):461-73.
5. Tuma Junior P, Faria JCM, Fontana C, Goldenberg DC, Ferreira MC. Queimaduras elétricas dos membros superiores. Rev Hosp Clin Fac Med Univ São Paulo. 1995;50 Supl:13-6.
6. Pitanguy I, Lima PV, Muller P, Persichetti P. Considerações sobre queimadura elétrica do lábio. Rev Bras Cir. 1986;76(4):231-42.
7. Morais-Besteiro J, Aki FE, Mendes JA. Retalhos livres pré-moldados. Rev Soc Bras Cir Plást. 1992;7(1):82-9.

---

#### Correspondence to:

Bruno Barros de Azevedo Coutinho  
Rua Razuk Jorge, 177 – Bandeirantes – Campo Grande, MS, Brazil – CEP 79006-530  
E-mail: bruno\_medicine@yahoo.com.br