



Closed platysmotomy: a 7-year review

Platysmotomia fechada: revisão de 7 anos

JOSÉ CARLOS DAHER^{1,2}
ISMAR RIBEIRO JÚNIOR^{1,2*}
BRUNO PEIXOTO ESTEVES^{1,2}
DHYEGO MOLINARI DI CASTRO
CURADO^{1,2}
RAFAEL QUARESMA DE LIMA^{1,2}
CONRADO MIRANDA DE ALMEIDA^{1,2}
LUCIANO GOMES MOURA^{1,2}

■ ABSTRACT

Introduction: The approach of the cervical region has remained challenging over the years. The closed platysmotomy technique, proposed by Daher, is a minimally invasive technique that offers a viable alternative to the approach of the cervical region, with low complication rates and lasting results over the years. The objective is to evaluate recurrent cases of platysmal bands over the years, including 7-year results. **Methods:** Photographic assessment was performed by a plastic surgeon blinded to the patient characteristics and the number of recurrences 7 years after surgery in all the female patients who underwent operation in our institution. The analysis was performed based on photographic documentation, and the results were classified as excellent, satisfactory, and unsatisfactory. The assessment did not involve patient participation. **Results:** The recurrence rates 7 years after surgery were similar to those found in traditional techniques. Of the cases, 57% were classified as excellent; 29%, as satisfactory; and 14%, as unsatisfactory. **Conclusion:** The closed platysmotomy technique is a valid alternative, with lasting results and the advantage of being a procedure with comorbidities fewer than those associated with the existing techniques, displaying similar recurrence rates over the years with other more invasive techniques.

Keywords: Rhytidoplasty; Neck muscles; Face; Neck.

■ RESUMO

Introdução: A abordagem da região cervical permanece desafiadora ao longo dos tempos. A platysmotomia fechada, proposta por Daher, é uma técnica minimamente invasiva, que oferece uma alternativa viável para abordagem da região cervical, com pequenas taxas de complicações e resultados duradouros ao longo dos anos. Avaliar as recorrências das bandas platismais ao longo dos anos, avaliado os resultados após 7 anos. **Métodos:** Avaliação fotográfica por um Cirurgião Plástico isento, que não conhecia as pacientes, quanto ao número de recidivas em 7 anos de cirurgia, em pacientes operados em nosso serviço, todas do sexo feminino. A análise foi feita por meio de

Institution: Hospital Daher Lago Sul,
Brasília, DF, Brazil.

Article received January 16, 2015.
Article accepted July 20, 2015.

DOI: 10.5935/2177-1235.2015RBCP0171

¹ Sociedade Brasileira de Cirurgia Plástica, São Paulo, SP, Brazil.

² Hospital Daher Lago Sul, Brasília, DF, Brazil.

documentação fotográfica, sendo os resultados classificados em excelentes, satisfatórios e insatisfatórios. Não houve participação das pacientes na avaliação. **Resultados:** Os índices de recidiva após 7 anos de cirurgia encontrados são semelhantes aos encontrados em técnicas já consagradas. 57% dos casos considerados excelentes, 29% satisfatórios e 14% insatisfatórios. **Conclusão:** A técnica da platismotomia fechada é uma alternativa válida, com resultados duradouros, e com a vantagem de ser um procedimento com menos comorbidades quando comparado com as técnicas existentes, mantendo-se os índices de recidiva ao longo dos anos semelhantes com outras técnicas mais invasivas.

Descritores: Ritidoplastia; Músculos do pescoço; Face; Pescoço.

INTRODUCTION

The first publication of a facial rejuvenation surgery dates back to 1917¹, with an elliptical skin excision, which became a commonly performed procedure with fairly limited results.

Over time, rhytidoplasties have undergone constant innovation and began to be widely used since the 1960s, particularly after a better understanding of the anatomy of the facial region, decreasing the risks of nerve lesions. The treatment of the cervical region, however, led to unsatisfactory results due to stigma for large scars.

The treatment design for the platysma muscle in facial rejuvenation surgeries was initially established by Guerrero-Santos in 1974, with the implementation of traction and securing the muscle to the mastoid region².

Since then, several authors have contributed different approaches to the treatment of the platysma muscle, including resections, total transections, and partial sutures with upper mountings or plicatures. All of these involve incisions in the submental or anterior cervical region, and cervical detachments at various levels³⁻¹⁰.

The closed platysmotomy technique, proposed by Daher in 2008, is a minimally invasive technique that has emerged with the aim of fulfilling the precise and specific treatment of platysma muscle bands, which are inactivated without incisions or submental detachment, and can be performed as an isolated procedure or in combination with rhytidoplasty.

OBJECTIVE

The objective of the present study was to review the cases operated in the Plastic Surgery Service of Hospital Daher Lago Sul, Brasilia, DF, Brazil, regarding the rate of recurrence of platysmal bands 7 years

after operation. All of the patients underwent closed platysmotomy, a technique proposed by Daher, either alone or in association with another surgery.

METHODS

A retrospective study was performed with analysis of pictures of patients who underwent closed platysmotomy alone or in combination with another surgery, by a plastic surgeon blinded to the cases. The patients did not participate in the analysis. Patients with less than 7 years after surgery were excluded from this study. The effectiveness of the procedure in the inactivation of platysmal bands was evaluated by performing a comparative analysis of preoperative and 7-year postoperative pictures, classified as “excellent,” “satisfactory,” and “unsatisfactory.” In cases classified as “excellent,” the platysmal bands completely disappeared. In the “satisfactory” cases, we observed a major improvement, but with traces of still visible platysmal bands. Finally, in cases considered “unsatisfactory,” we observed no improvement of platysmal adhesions, similarly to those observed in the preoperative period.

Approval by zip code was not necessary because this was a retrospective study, based on the analysis of the pictures of the patients who underwent operation 7 years prior. One must note that the surgical technique used in this study has been widely publicized and consolidated in national and international literatures, with approval for use. Free and informed consent was also not necessary, for the same reason mentioned earlier on the CEP.

RESULTS

This study was conducted in 2014, in the Department of Plastic Surgery, Hospital Daher Lago

Sul. Seven female patients who met the inclusion criteria (7 years after surgery) were selected, with a mean age of 56 years. Of the 7 patients, 3 underwent closed platysmotomy as an isolated procedure and 4 underwent closed platysmotomy associated with rhytidoplasty. The standard postoperative follow-up time was 1 month, 2 months, 6 months, 1 year, and 7 years. The results are shown in Figure 1.

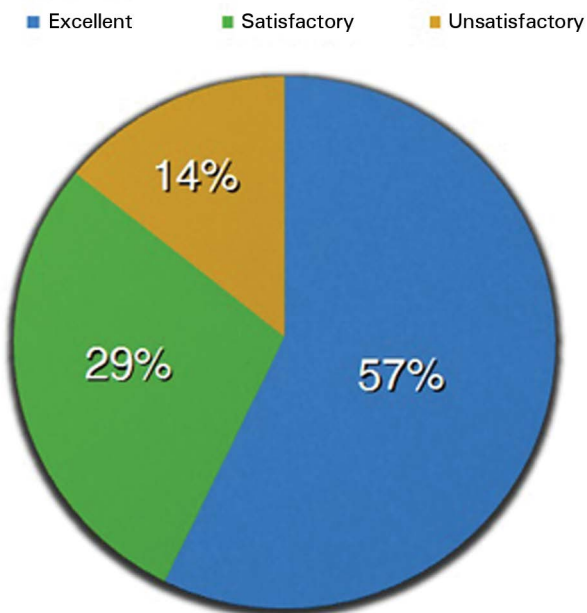


Figure 1. Percentage of cases in each classification.

In cases classified as “excellent,” we observed complete disappearance of the platysmal bands, without recurrence after 7 postoperative years, as shown in Figure 2. The patients who achieved “satisfactory” results showed disappearance of the platysmal bands, with good aesthetic end results but with some sign of the bands upon strict observation, both bilaterally and unilaterally (Figure 3). In the patients with “unsatisfactory” results, the platysmal bands recurred after 7 years, as shown in Figure 4.

DISCUSSION

The history of treatment of the cervical region shows us the contribution of various pioneering authors in refinements of the skin, platysma, SMAS, and adipose tissue. Millard et al.¹¹ in 1968, with the cervical lipectomy; Guerrero-Santos² in 1974, with muscular flaps traction toward the mastoid; Peterson¹² in 1978, with sections and lateral tractions of the platysmal muscle; Aston and Kaye^{4,5} in 1981, with medial and lateral sections of the platysma muscle; Connell³ in 1983, with the total sectioning of the platysma muscle;

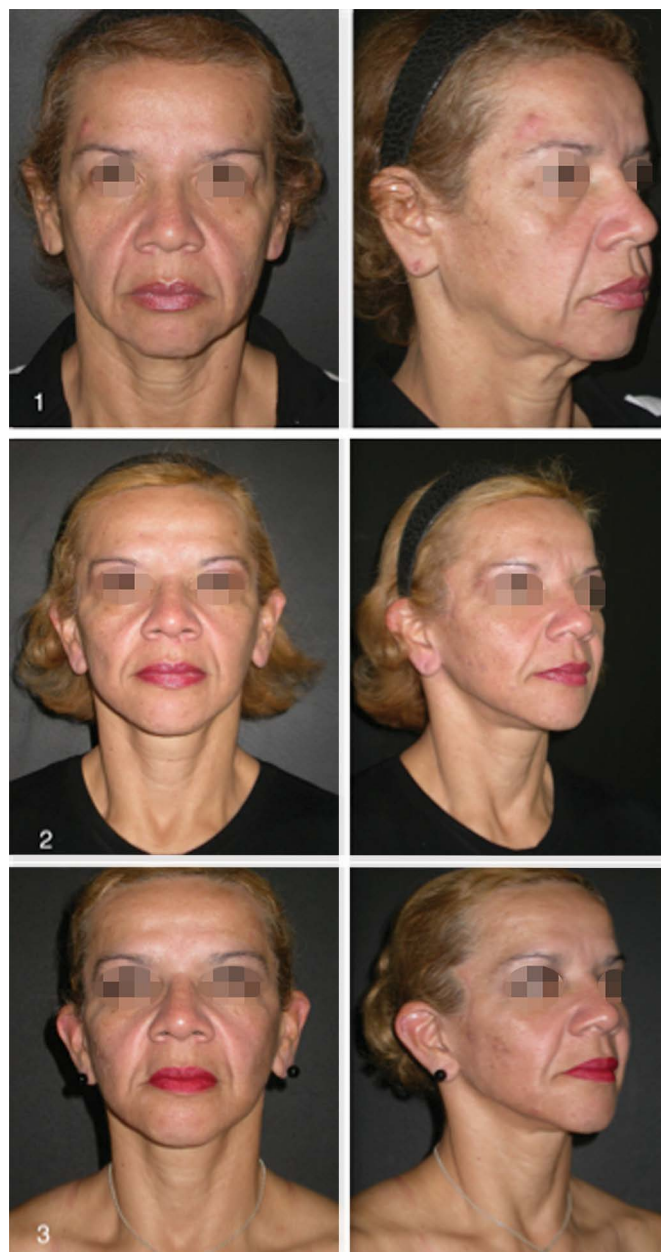

Figure 2. Excellent results. 1. Preoperative. 2. Postoperative period of 1 year. 3. Postoperative period of 7 years.

Cardoso de Castro⁹ in 1983, with the anatomical studies in the cervical region and sutures toward the cervical midline and Fogli¹³, with the lateral anchoring of the SMAS in Lore’s fascia, among others, are some of these examples.

In the analysis of the results of facial rejuvenation, the neck is often ignored, as it is covered with necklaces or clothing during the preoperative evaluation. The results of surgical follow-up, in accordance with the literature, often show a poor definition of the lower third of the neck with stubborn wrinkles and platysmal bands, although a better definition of the contour of

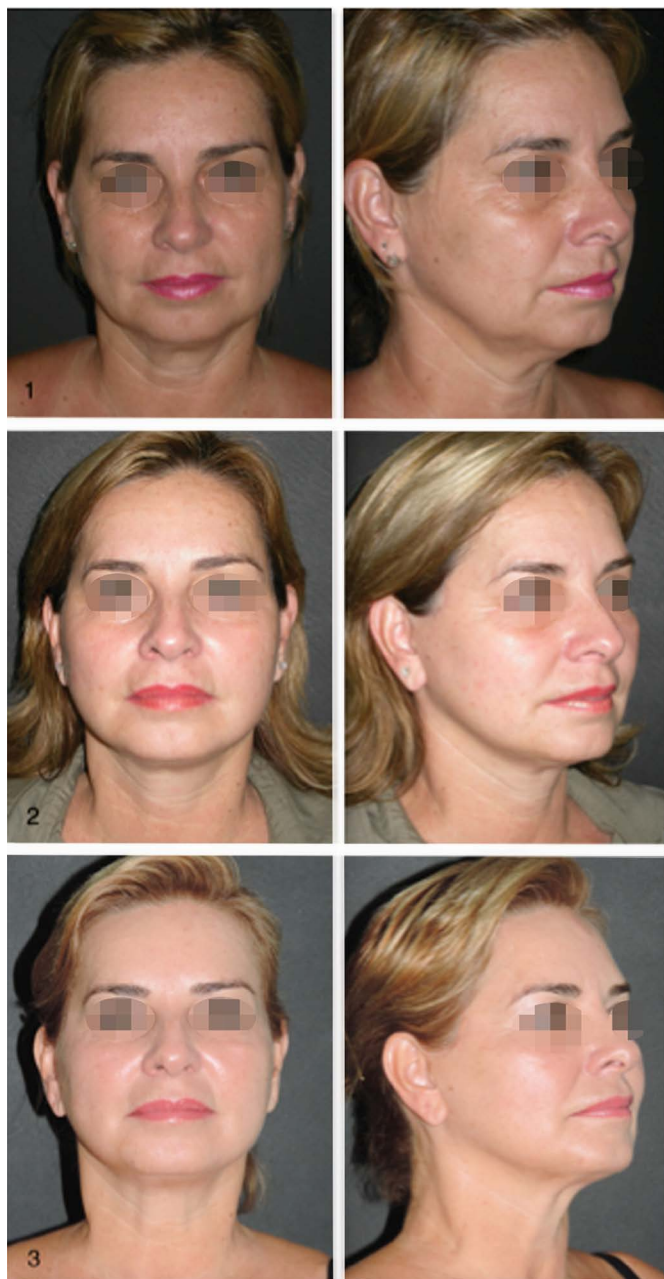

Figure 3. Satisfactory result. 1. Preoperative. 2. Postoperative period of 1 year. 3. Postoperative period of 7 years.

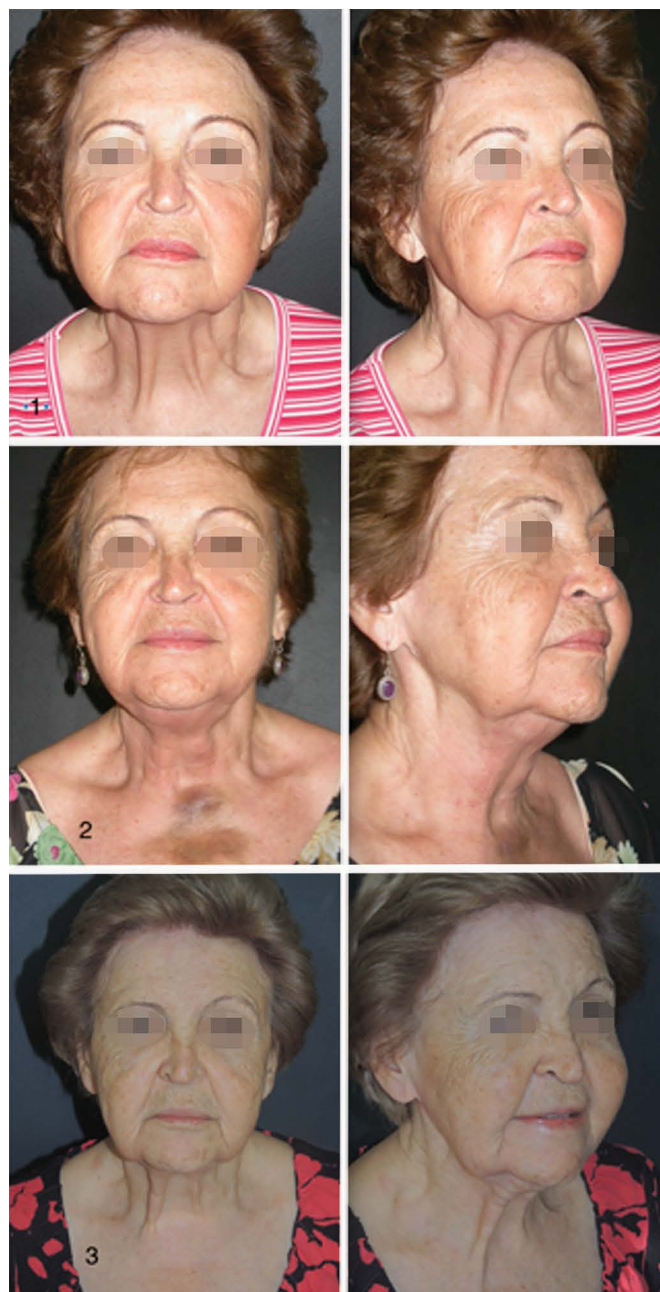

Figure 4. Unsatisfactory outcome. 1. Preoperative. 2. Postoperative period of 1 year. 3. Postoperative period of 7 years.

the jaw is achieved. The lower third of the neck, when tense, full and defining the entire sternocleidomastoid, is a characteristic of desirable beauty, accepted universally¹⁴.

In order to achieve these goals, Daher, in 2008, created and started to use the closed platysmotomy technique as a procedure of choice in the treatment of platysmal bands. The technique has been demonstrated to be excellent because of the advantages it can offer, such as short surgical time and absence of large scars in the cervical region, only punctiform holes, without

the need for sutures. Furthermore, it is considered to be less invasive and low-cost, as it can be conducted in an outpatient basis with local anesthetic. This means that in these cases, the patients should be selected with care.

Another advantage of this technique is the low incidence of complications, including small and non-expansive cervical hematomas, and can be easily resolved by puncture or manual draining¹⁵.

After a 7-year postoperative period, we observed a low rate of recurrence of platysmal bands with the

use of closed platysmotomy (14%), consistent with the rates found in another study by Cárdenas-Camarena et al.¹⁶, with 11% unsatisfactory results in 33 months. Other studies with a shorter follow-up duration also presented a certain recurrence rate, according to Labbé et al.¹⁷ (satisfactory results in 12 months) and Guyron et al.¹⁸, with 20 months of follow-up, without recurrences. The literature still needs studies with an extended follow-up in order to better assess the recurrences of the approach of the cervical region.

The recurrences occurred in cases regarded as difficult, as in the study of Guyron et al.¹⁸, where the patients had redundant skin, important ptosis of the digastric muscle, excess adipose tissue, and severe hypertrophy of the platysmal bands.

The recurrences may be easily readdressed, if the patient desires it, by using the Daher technique, without major difficulties and without the need for extensive detachment. One should note that the technique has limits; it does not guarantee that reappearance of bands would not occur, as in other open techniques.

CONCLUSION

The rejuvenation of the neck continues to be a challenge because it is an area of high aesthetic importance owing to its constant visual exposure. The commitment to ensure consistent, effective, long-lasting, natural-looking results is shared by all the surgeons.

Closed platysmotomy resulted with these precepts and has been demonstrated to be useful in the treatment of platysmal bands with consistent results, but not lasting, as shown in this study with 7 years of follow-up, but with the advantage of being less invasive, with low rates of complications, without visible scars on the neck, and is therefore an excellent approach for dealing with primary cases and relapses of platysmal bands, with long lasting results over the years. One must note that the results of the closed technique are not eternal, as with the already known open techniques.

REFERENCES

1. Passot R. La correction chirurgicale des rides du visage. *Bull Acad Med.* 1919;2:112-6.
2. Guerrero-Santos J, Espaillet L, Morales F. Muscular lift in cervical rhytidoplasty. *Plast Reconstr Surg.* 1974;54(2):127-30. PMID: 4843119 DOI: <http://dx.doi.org/10.1097/00006534-197408000-00001>
3. Connell BF. Contouring the neck in rhytidectomy by lipectomy and a muscle sling. *Plast Reconstr Surg.* 1978;61(3):376-83. DOI: <http://dx.doi.org/10.1097/00006534-197803000-00011>
4. Aston SJ. Platysma muscle in rhytidoplasty. *Ann Plast Surg.* 1979;3(6):529-39. PMID: 397794 DOI: <http://dx.doi.org/10.1097/00006534-197912000-00007>
5. Aston SJ. Platysma-SMAS cervicofacial rhytidoplasty. *Clin Plast Surg.* 1983;10(3):507-20. PMID: 6354554
6. Vistnes LM, Souther SG. The platysma muscle. Anatomic considerations for aesthetic surgery of the anterior neck. *Clin Plast Surg.* 1983;10(3):441-8. PMID: 6627838
7. Biggs TM, Koplin L. Concepts of neck lift. *Clin Plast Surg.* 1983;10(3):367-78. PMID: 6627833
8. McKinney P, Tresley GE. The "maxi-SMAS": management of the platysma bands in rhytidectomy. *Ann Plast Surg.* 1984;12(3):260-7. DOI: <http://dx.doi.org/10.1097/00006534-198403000-00008>
9. Cardoso de Castro C. The value of anatomical study of the platysma muscle in cervical lifting. *Aesthetic Plast Surg.* 1984;8(1):7-11. DOI: <http://dx.doi.org/10.1007/BF01572778>
10. Feldman JJ. Corset platysmaplasty. *Plast Reconstr Surg.* 1990;85(3):333-43. PMID: 2304983 DOI: <http://dx.doi.org/10.1097/00006534-199003000-00001>
11. Millard DR, Pigott RW, Hedo A. Submandibular lipectomy. *Plast Reconstr Surg.* 1968;41(6):513-22. PMID: 5654894 DOI: <http://dx.doi.org/10.1097/00006534-196806000-00001>
12. Peterson RA. The role of platysma muscle in cervical lifting. In: Goulian P, Courtis E, eds. *Symposium of surgery of the aging face.* St Louis: Mosby; 1978. p.115-24.
13. Fogli AL. Skin and platysma muscle anchoring. *Aesthetic Plast Surg.* 2008;32(3):531-41. PMID: 18305986 DOI: <http://dx.doi.org/10.1007/s00266-007-9111-9>
14. Hodgkinson DJ. Five-year experience with modified Fogli (Loré's fascia fixation) platysmaplasty. *Aesthetic Plast Surg.* 2012;36(1):28-40. DOI: <http://dx.doi.org/10.1007/s00266-011-9772-2>
15. Daher JC. Closed platysmotomy: a new procedure for the treatment of platysma bands without skin dissection. *Aesthetic Plast Surg.* 2011;35(5):866-77. DOI: <http://dx.doi.org/10.1007/s00266-011-9782-0>
16. Cárdenas-Camarena L, González LE. Multiple, combined plications of the SMAS-Platysma Complex: breaking down the face-aging vector. *Plast Reconstr Surg.* 1999;104(4):1093-100. DOI: <http://dx.doi.org/10.1097/00006534-199909020-00033>
17. Labbé D, Franco RG, Nicolas J. Platysma suspension and platysmaplasty during neck lift: anatomical study and analysis of 30 cases. *Plast Reconstr Surg.* 2006;117(6):2001-7. DOI: <http://dx.doi.org/10.1097/01.prs.0000218972.75144.9c>
18. Guyron B, Sadek EY, Ahmadian R. A 26-year experience with vest-over-pants technique platysmarrhaphy. *Plast Reconstr Surg.* 2010;126(3):1027-34. DOI: <http://dx.doi.org/10.1097/PRS.0b013e3181e3b6a1>

*Corresponding author:

Ismar Ribeiro Júnior

Quadra Shis, QI 07, Conjunto F - Lago Sul - Brasília, DF, Brazil

Zip Code 71615-570

E-mail: ismarjr@gmail.com